

# Acute Toxicity and Histopathological Evaluation of Seed and Stem Bark Extracts of *Carapa procera* D.C Meliaceae on Liver and Kidney of Male Wistar Rats.

<sup>1,2</sup>Azibanasamesa D.C Owaba, <sup>3</sup>Abraham S. Eboh, <sup>4</sup>Emmanuel C. Ugwoke, <sup>4</sup>Cyril Ogbiko

<sup>1</sup>Department of Pharmaceutical and Medicinal Chemistry, Faculty of Pharmacy, Niger Delta University, Wilberforce Island Bayelsa State, Nigeria.

<sup>2</sup>Department of Pharmaceutical and Medicinal Chemistry, Faculty of Pharmacy, University of Uyo, Uyo, Akwa-Ibom State, Nigeria.

<sup>3</sup>Department of Biochemistry, Faculty of Basic Medical Science, Niger Delta University, Wilberforce Island, Bayelsa State, Nigeria.

<sup>4</sup>Department of Pharmaceutical Chemistry, Faculty of Pharmacy, Madonna University, Elele, Rivers State, Nigeria.

## ABSTRACT

**Background:** *Carapa procera* D.C belongs to the family of Meliaceae is a medicinal plant used in the Ijaw area of Niger Delta for the management of diseases; seed for malaria while decoction of stem bark for erectile dysfunction in ethnomedicine. The aim of study is to assess the safety, toxicity on the liver and kidney in order to corroborate and regulate the use in humans.

**Method:** The seed and stem bark were extracted using n-hexane, dichloromethane, and 70% methanol via successive cold maceration. Acute toxicity profile was determined using the Lorke's method. The LD<sub>50</sub> for the crude seed and stem bark extract were determined to be at 866.03 and 447.21 mg/kg. Various doses of the LD<sub>50</sub> (10, 20 and 30%) were administered daily to ninety male rats orally for 7 days. On the 8<sup>th</sup> day it was anaesthetized using chloroform, sacrificed, liver and kidney harvested for histological evaluation.

**Results:** The histological assessment revealed no distortion in organs assessed when compared to control except the high dose crude seed extract which showed signs of toxicity.

**Conclusion:** The crude seed extract at high dose affect the liver due to distortion, steatosis and should not be used while at low and medium dose showed no alteration in the hepatic architecture.

Keywords; *Carapa procera*, Histopathology, Acute toxicity, Liver, Kidney

## 1. INTRODUCTION

Paul Ehrlich, the German Physician and Bacteriologist began the systemic search for a "magic bullet" coined to explained chemical or biological substance with a specific harmful effect on the pathogen without affecting the host cells and tissues [1]. Numerous drug substances are utilized to control and eradicate various diseases and a magic bullet that could interact with a specific receptor without any harmful effect on organs and tissues is yet to be discovered [2]. The aim of administering medicinal substances is to elicit a definite therapeutic effect that would improve the patient quality of life. Drug substances tend to affect the kidney and liver because of their role in bio-activation, metabolism and excretion [3]. The harmful effect of certain substances on the liver and kidney could lead to failure of the organ to fulfill its biological function. The aim of study is to pinpoint the safety, toxicity of seed and stem bark extracts of *Carapa procera* D.C Meliaceae on the histopathological effect of liver and kidney in male wistar albino rats, in order to corroborate it's effects in humans using this medicinal substance as an antimalarial and aphrodisiac agent in ethnomedicine by the Ijaws of Southern Nigeria.

---

\*Corresponding author: Email:[azibanasamesa@gmail.com](mailto:azibanasamesa@gmail.com); Phone:+2348064578188

# Owaba et al: Acute Toxicity and Histopathological Evaluation of Seed and Stem Bark Extracts of *Carapaprocera* D.C Meliaceae on Liver and Kidney of Male Wistar Rats

## 2. MATERIALS AND METHODS

### 2.1 Material

#### 2.1.1 Chemical and Reagents

All reagents, drugs and materials were obtained for standard pharmaceutical and chemical outlets.

### 2.2. Methods

#### 2.2.1. Collection and Identification of Plant Materials

The collection and identification of the plant was carried out as reported by Owaba *et al* [4-5].

#### 2.2.2 Extraction

The dried seed and stem bark were extracted by adopting and using the protocol reported by Owaba *et al* [4-5].

#### 2.2.3 Acute Toxicity Studies

The Lorke's Method was used to determine acute toxicity test in mice with slight modification to establish LD<sub>50</sub> of the extracts. Thirty nine mice weighing 16-24 g were divided into six groups (n = 3) and 70% Methanol crude stem bark extract were administered intraperitoneal at 100, 200, 300, 400, 500, 1000 mg/kg body weight respectively and 1 hour after the administration of the extract the animals allowed free access to water, food and monitored for harmful signs; writhing, immobility, abated respiration and death. The death rate recorded within 24 hours. This was repeated for 70% Methanol crude seed extract at the following doses; 250, 500, 750, 1000, 2000, and 3000 mg/kg [6-9].

#### 2.2.4. Experimental Animals

The experimental protocol as reported by Owaba *et al* [5] was adopted and adhered to strictly. The male wistar rats were divided into fifteen groups (n = 6), various doses of the crude seed extract, stem bark extract, fractions, distilled water and standard drug (testosterone) were given daily for 7 days using standard laboratory procedures as stated by the University of Uyo, animal ethical committee [5]. The experimental animals on the 8th day were anaesthetized using chloroform, sacrificed, liver and kidneys harvested, preserved in 10%(v/v) formalin for histological appraisal [4, 10-14]. The samples were given using the outline; Group I- II DIST = (10 ml/kg of distilled water) and 1 mg/kg Testosterone (TET); Group III- V-LDcba = Low dose crude stem bark extract 44.72 mg/kg; MDcba = Median dose crude stem bark extract 89.44 mg/kg; HDcba = High dose crude stem bark extract 134.16 mg/kg/day given respectively. Group VI- VIII (n-Hexba = n-Hexane fraction; DCMba = Dichloromethane fraction, MTba = Methanol stem bark fraction respectively. The seed extracts, the following outline was used in administration. Group IX-XI; were given LDcsa = Low dose crude extract 86.60 mg/kg; MDcsa = Median crude seed extract 173.21 mg/kg; HDcsa = High dose crude seed extract 259.81 mg/kg, respectively while group XII-XV were given various fractions at 173.21 mg/kg/day (n-Hexsa = n-Hexane seed fraction; DCMsa = Dichloromethane seed fraction; MTOsa = Methanol seed oil; MTsa = Methanol seed fraction. All the extracts and fraction were given daily for 7 days.

## 3.0 RESULTS

### 3.1 Results of Acute Toxicity of Seed and Stem Bark Extracts of *Carapa procera*

Table 1.0: Result of Acute toxicity of crude stem bark extract of *Carapa procera*

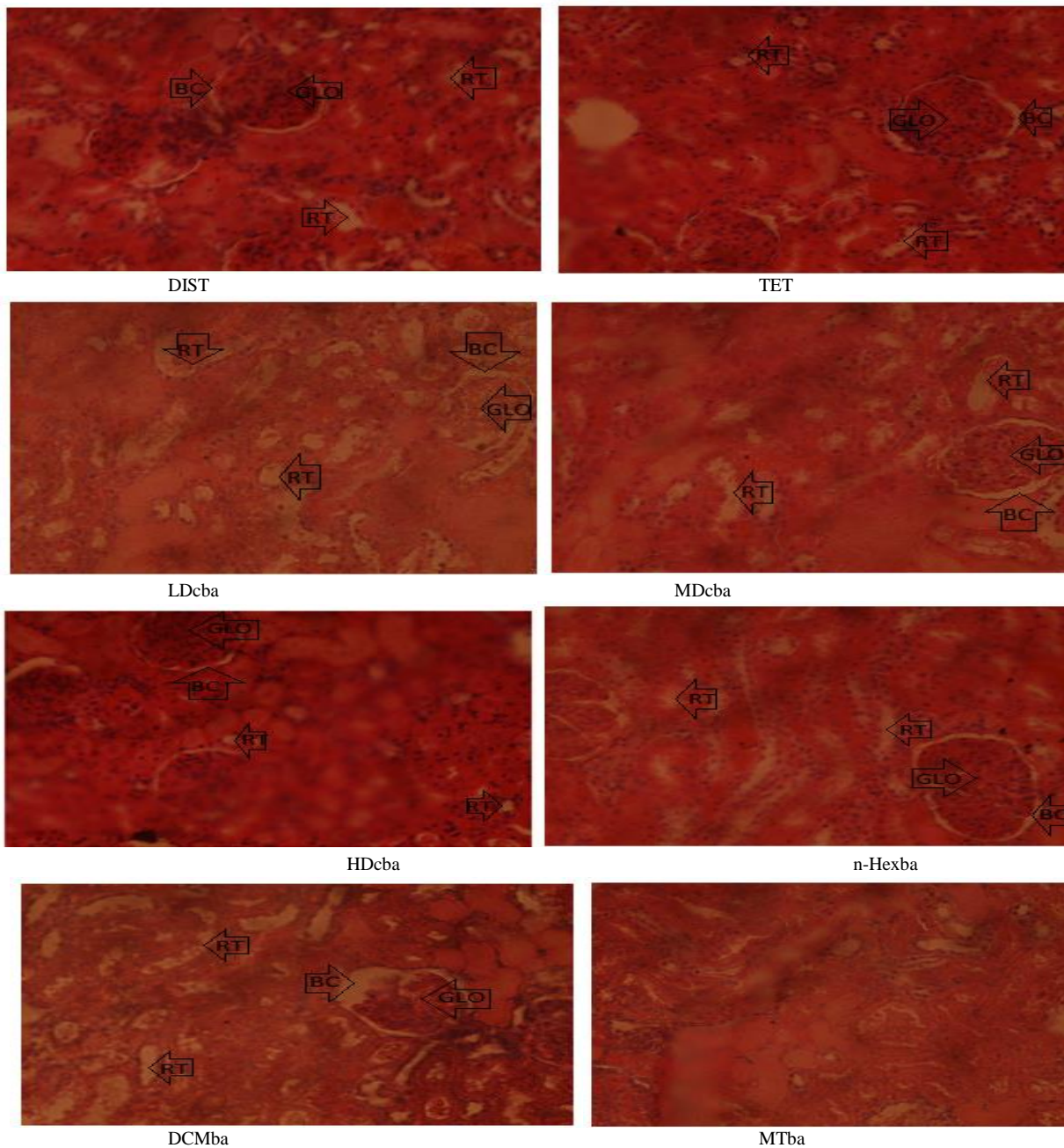
S/N	Dose administered(mg/kg)	Ratio	No. of Death
1	100	0/3	0
2	200	0/3	0
3	300	0/3	0
4	400	0/3	0
5	500	3/3	3
6	1000	3/3	3

Table 2.0: Result of Acute toxicity test of 70% Crude methanol Seed extract in rats

S/N	Dose administered (mg/kg)	Ratio	No. of Death
1	250	0/3	0
2	500	0/3	0
3	750	0/3	0
4	1000	3/3	3
5	2000	3/3	3

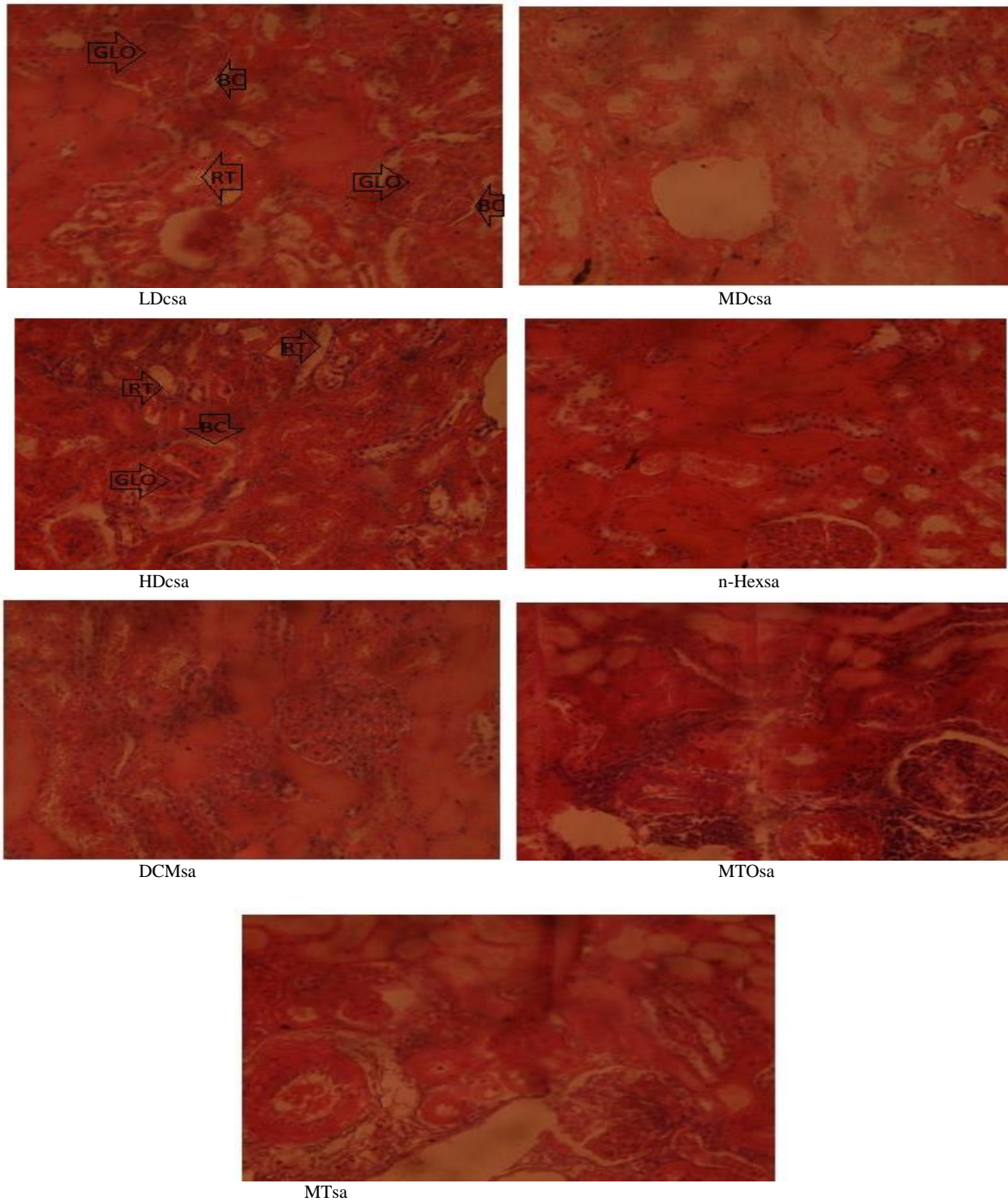


*3.2 Results of Histological Effect of Seed and Stem Bark Extracts on the Kidneys*





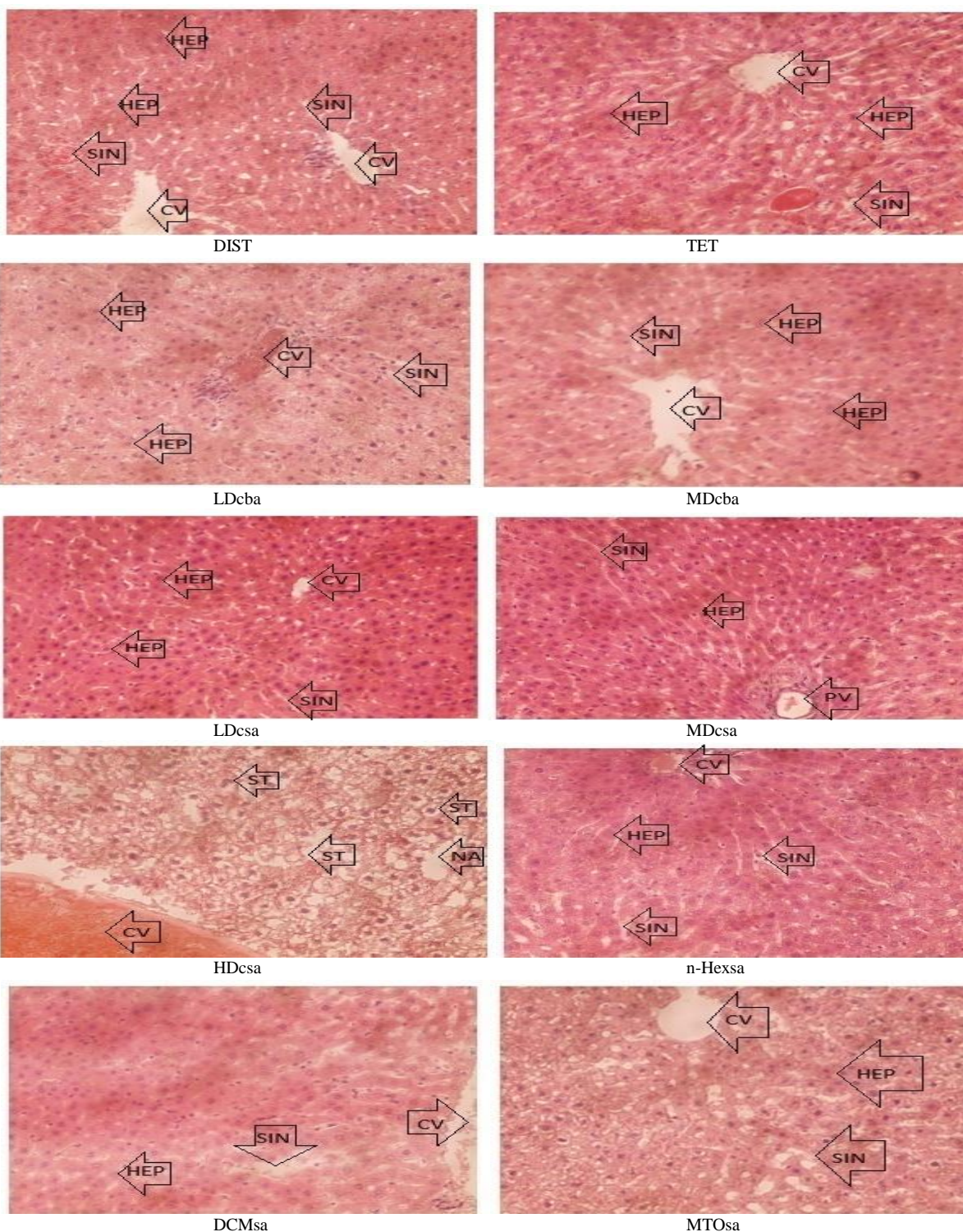
**Owabaet al: Acute Toxicity and Histopathological Evaluation of Seed and Stem Bark Extracts of *Carapaprocera* D.C Meliaceae on Liver and Kidney of Male Wistar Rats**



Keys: GLO = Glomerulus, BC = Bowmens Capsule, RT =Renal tubule.

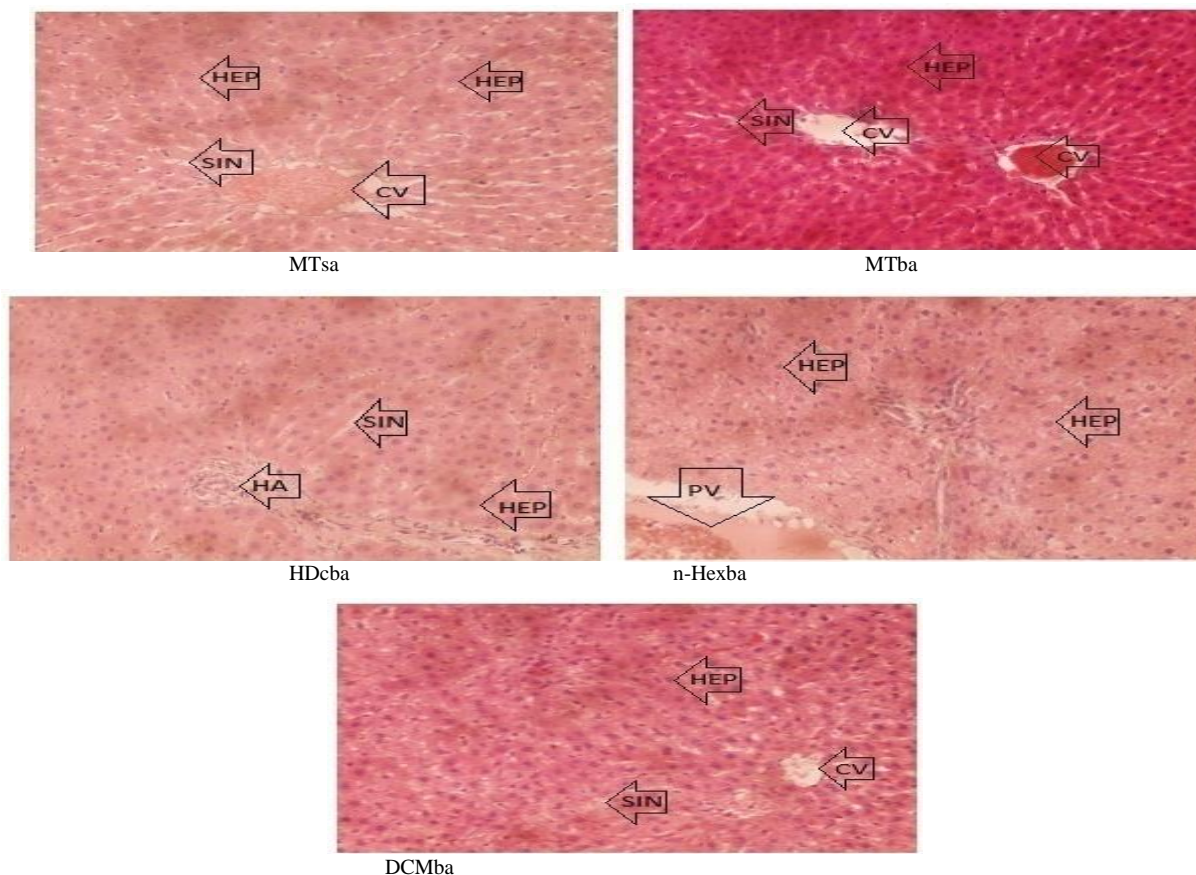
Figure 1: Histological effect of the crude extracts and fractions of *Carapa procera* on the kidneys (Photomicrograph, H&Ex400)

*3.3 Results of Histological Effect of Seed and Stem Bark Extracts on the Liver*





**Owabaet al: Acute Toxicity and Histopathological Evaluation of Seed and Stem Bark Extracts of *Carapaprocera* D.C Meliaceae on Liver and Kidney of Male Wistar Rats**



Keys; Hep = Hepatocytes, Sin = Sinusoids, CV = Central vein, PV= Portal vein, HA = Hepatic artery, ST = Steatosis

Figure 2.0: Histological effect of seed and stem bark extracts of *Carapa procera* on the liver (Photomicrograph, H&Ex400)

Table 3.0: Summary of the results of histological evaluation of *Carapa procera* seeds and stem bark extracts on the kidney

S/N	Samples	Organs	Comment
1.	Control (H <sub>2</sub> O)	Kidney	All the extracts and samples assessed showed, no sign of toxicity on kidney. The histological assessment showed normal kidney with standard features such as normal glomerulus, renal tubules, and bowman capsules, this implies that <i>Carapa procera</i> stem bark and seeds extracts are not nephrotoxic when administered at the experimental dose for seven days compared to control and standard drug.
2.	TET		
3.	Stem bark		
4.	Seed Extracts		

Table 4.0: Summary of the results of histological evaluation of *Carapa procera* seeds and stem bark extracts on the liver

S/N	Sample	Organ	Comment
1.	Control(H <sub>2</sub> O)	Liver	The stem bark and seeds extracts showed no toxic effect on the hepatic cells and tissue, however, the crude extract of the seed at high dose showed severely distorted liver and hepatocytic steatosis, necrotic areas, and congested central vein. This implies that consumption of the crude seed extract at high dose could lead to hepatic damage, however, at low and median dose no sign of toxicity observed.
2.	TET		
3.	Stem bark		
4.	Seed Extract		

#### **4.0 DISCUSSION**

The crude seed and stem bark extracts had an LD<sub>50</sub> of 866.03 and 447.21 mg/kg (Table 1.0 and 2.0) respectively. This showed that the extracts were slightly to moderately toxic respectively [9]. The histological assessment showed normal kidney with standard features such as normal glomeruli, renal tubules, and bowman capsules, this implies that *Carapa procera* stem bark and seeds extracts were not nephrotoxic (Table 3.0), when administered, at the experimental dose for seven days compared to control (Figure 1.0). The stem bark and seeds extracts showed no signs of toxicity on the hepatic cells and tissues, however, the crude seed extract at high dose (HD<sub>CSA</sub>) showed severely distorted liver, and hepatocytic steatosis, necrotic areas, and congested central vein (Table 4.0). This implies that consumption of the crude seed extract at high dose could lead to hepatic damage, however, at low and median dose no sign of toxicity was observed as shown in Figure 2.0 [15-20]

#### **5.0 CONCLUSION**

The extracts of the seed and stem bark are slightly to moderately toxic as revealed by the acute toxicity studies. The histological assessment of the extracts showed that at high dose the seed extracts caused distortion and steatosis in the liver. However, no sign of toxicity was observed at various doses administered for the crude and fractions of samples.

#### **Acknowledgements**

We are grateful to Dr. Emmanuel I. Etim, Dr. Ekarika C. Johnson, Mr. Nsikan M. Udo, Faculty of Pharmacy, University of Uyo, Uyo, for their immense contribution.

#### **Funding**

This work was funded by TETFund.

#### **Conflict of interest**

We declare no conflict of interest.

#### **Contribution of the Authors**

All authors design and implement the Study. Owaba ADC, carried out the experiments and writing of the manuscript while Eboh, AS, Ugwoke EC, Ogbiko C supervised the experiments, interpreted results and edited manuscript.

#### **6.0 REFERENCES**

- [1] Nester E W, Anderson DG, Roberts CE, Pearsall, NN, Nester MT, Hurley D. Microbiology, A Human Perspective 4<sup>th</sup> Edition, McGraw Hill Company, Newyork, 2004; 507-532.
- [2] Kirchain WR, Gil MA. Drug induced liver disease. In: Pharmacotherapy: A pathophysiological approach. DiPiro, J.T., Talbert, R.L., Yee, G.C., Matzke, G.R., Wells B.G., and Posey, L.M. McGraw Hill Medical Publishing Division, Newyork, 2015; 750-757.
- [3] Akah P A. Drug Absorption, Distribution and Biotransformation In: Akubue P.I(Editor) Textbook of Pharmacology. AFP, Onitsha, 2005; 2-15p.
- [4] Owaba ADC, Etim EI, Umoh UF. The Effect of Stem Bark Extracts of *Carapaprocera* D.C Meliaceae on Hormonal and Biochemical Parameters in Male Albino Wistar Rats. *International Journal of Pharmacy and Pharmaceutical Research*, 2021;21(2):276-284.
- [5] Owaba A.D.C, Etim, E. I Johnson E.C. Comparative Haematological Effect of Seed and Stem Bark Extracts of *CarapaProcera* D.C Meliaceae in Male Rodents. *The Journal of Phytopharmacology*, 2022; 11(1): 137-141.
- [6] Lorke D. A new approach to practical acute toxicity testing. *Archives of Toxicology*. 1983; 54, 275 – 287
- [7] Okokon EJ, Udoh EA, Frank GS, Udo MN. Anti-inflammatory and antipyretic activities of *Panicum maximum*. *African Journal of Biomedical Research*, 2011; 14, 125 - 130.
- [8] Chinedu E, Arome D, Ameh E S. A new method for determining acute toxicity in animal models. *Toxicol International*, 2013; 20(3): 224-226.

## Owabaet al: Acute Toxicity and Histopathological Evaluation of Seed and Stem Bark Extracts of *Carapaprocera D.C Meliaceae* on Liver and Kidney of Male Wistar Rats

- [9] Erhirhie EO, Ihekwereme CP, Illodigwe EE. Advances in acute toxicity testing: strengths, weakness and regulatory acceptance. *Interdisciplinary Toxicology*, 2018; 11(1): 5-12. Doi 10.2478/intox-2018-0001.
- [10] Etuk EU, Mohammad AA. Fertility enhancing effects of aqueous stem bark extract of *Lophiralanceolata* in male Sprague-Dawley rats. *International Journal of Plant Physiology and Biochemistry*. 2009; (1): 001-004.
- [11] Ezz-Din D, Gabry MS., Farrag ARH, Moneim AEA. Physiological and histological impact of *Azadirachta indica* (neem) leaves extract in a rat model of cisplatin induced and nephrotoxicity. *Journal of Medicinal Plants Research*. 2011; 5(23): 5499-5506.
- [12] Najam W S. (2012). Significant value of hormonal assays as marker for male infertility in Tikrit City. *Tikrit Medical Journal*. 18(2): 314-321.
- [13] Dumaro C A, Etim E, Ahmadu, AA. Anti-inflammatory constituents of *Randia hispidia*, K. Schum Rubiaceae. *Journal of Chemical and Pharmaceutical Research*, 2017; 9(2): 160-164
- [14] Ngwu O E, Okoye JI Comparative evaluation of selected medicinal plants on fertility indices reproductive hormones and sperm profile of albino wistar rats: Animal case study. *International Journal of Plants and Soil Science*, 2019; 29(2): 1-6.
- [15] Dapar MLP, Wannang NN, Gyang, SS, Tanko, MN. The histopathologic effects of *Securidacalongo pedunculata* on heart, liver, and lungs of rats. *African Journal of Biotechnology*, 2007; 6(5): 591-595.
- [16] Galam NZ, Gambo I M, Habeeb AA, Shugaba AI. The effect of Aqueous extract of *Garcinia kola* seed on the liver histology. *Journal of Natural Science Research*. 2013; 3(1): 81-87.
- [17] Aboonabi A, Rahmat A, Othman F. Effect of pomegranate on histopathology of liver and kidney on generated oxidative stress in diabetic induced rats. *Journal of Cytology and Histology*, 2014; 6(1): 1-5. Doi 10.4172/2157-7099.1000294.
- [18] Yaman T, Uyar A, Celik I, Alkan EE, Keles OF, Yener Z. Histopathological and Immunohistochemical study of antidiabetic effect of *Heracleum persicum* extract in experimentally diabetic rats. *Indian Journal of Pharmaceutical Education and Research*. 2017; 51(3): S450-457.
- [19] Adelakun SA, Ogunlade B, Omotoso OD. Histomorphological responses to aqueous crude leaf extract of *Alafia barteri* on prefrontal cortex, heart, kidney, liver and testis of adult male Sprague Dawley rats. *European journal of Biological Research*, 2018; 8(2): 105-111.
- [20] Nwafor PA. *My interswitch from fertility regulating plants contraceptives to aphrodisiacs*. 69<sup>th</sup> Inaugural Lecture of the University of Uyo, Uyo. The University of Uyo Press Ltd, Uyo, Nigeria. 2019; 1-138p.